

Intractable Gastrointestinal Bleeding from Angiodysplasia in a Patient of Bernard-Soulier Syndrome —Report of a Case—

Riki OKITA^{1,*}, Jun HIHARA¹⁾, Kazuo KONISHI¹⁾, Akihiko OSAKI¹⁾, Kazuhiro YOSHIDA¹⁾,
Yoshiyuki YAMAGUCHI¹⁾, Tetsuya TOGE¹⁾, Kingo FUJIMURA²⁾, Takashi IWATA³⁾
and Akihiro SAWAMURA³⁾

1) Department of Surgical Oncology, Research Institute for Radiation Biology and Medicine, Hiroshima University

2) Division of Clinical Pharmacotherapeutics, Program for Applied Biomedicine, School of Biomedical Sciences, Hiroshima University, Kasumi 1–2–3, Minami-ku, Hiroshima 734–8551, Japan

3) Department of Surgery, Shimura Hospital, Funairi-chou 3–13, Naka-ku, Hiroshima 730–0841, Japan

ABSTRACT

We herein report a case of gastrointestinal bleeding induced by angiodysplasia of the cecum in a case of Bernard-Soulier syndrome with recurrent breast cancer. In spite of endoscopic hemostatic therapy and interventional embolization, she had repeated massive bleeding from the cecal lesion. In addition, she had chronic hepatitis C and progressive liver tumors metastasized from breast cancer, and she finally died of hepatic failure. There are four case reports in the literature describing Bernard-Soulier syndrome with gastrointestinal bleeding angiodysplasia. The reported cases benefited from hormonal, endoscopical hemostasis and surgical therapy. In our case, because of her terminal metastatic breast cancer, only conservative treatments were administered after the third bleed. Both the endoscopic hemostatic method and interventional embolization showed only a temporary effect. Surgical treatment should be considered if the general condition can tolerate a surgical procedure.

Key words: Bernard-Soulier syndrome, Gastrointestinal bleeding, Angiodysplasia, Interventional embolization, Breast cancer

Bernard-Soulier syndrome (BSS) is an autosomal recessive bleeding disorder characterized by giant platelets, thrombocytopenia, and prolonged bleeding, and is a very rare disorder found in less than 1 in a million people^{3,6)}. We present a case of BSS with recurrent breast cancer showing gastrointestinal (GI) bleeding induced by angiodysplasia of the cecum. There are four case reports in the literature describing BSS complicated by GI angiodysplasia and no reports describing BSS complicated by a malignant disease.

CASE REPORT

A 48-year-old Japanese woman who had been diagnosed with BSS (Table 1) and chronic hepatitis C in our hospital 6 years earlier and had undergone a modified radical mastectomy with stage IIB breast cancer (UICC-TNM)¹⁰⁾ 2 years earlier, was diagnosed with metastatic disease in the liver, lung and bone. In spite of several admin-

istrations of chemotherapy and endocrine therapy, her disease gradually worsened. She was admitted to Shimura Hospital complaining of severe melena, general fatigue and showed bone marrow suppression as an adverse effect of an anticancer agent. A transfusion of red blood cells was performed for severe anemia. To locate the bleeding point, colonoscopic examination was performed and revealed a single bleeding spot in the cecum. The bleeding was stopped temporarily by endoscopic hemostatic therapy with local injection of a polidocanol and spray with thrombin, but melena recurred the next day. She was transported to Hiroshima University Hospital for further evaluation. As she refused a colonoscopic hemostatic procedure because of abdominal pain during the previous colonoscopy due to the adhesion of peritoneal dissemination or peritoneal endometriosis, interventional radiology was selected. Selective mesenteric angiography was performed and a site

*Correspondence to: Riki Okita, MD: Department of Surgical Oncology, Research Institute for Radiation Biology and Medicine, Hiroshima University, Kasumi 1–2–3, Minami-ku, Hiroshima 734–8551, Japan.
Tel: +81–82–257–5869, Fax: +81–82–256–7109
E-mail: rokita@hiroshima-u.ac.jp

Table 1. Laboratory data on diagnosing with Bernard-Soulier syndrome

WBC (/mm ³)	7400	Bleeding time (min)	20<
RBC ($\times 10^4$ /mm ³)	454	(thinplate method)	
Hgb (g/dl)	11.1		
Ht (%)	34	Platelet morphology	giant [#]
Plt ($\times 10^3$ / μ l)	60	vWF activity	normal
		GP IIb/IIIa	+
Prothrombin time (sec)	11.2s	GP Ib α	- [#]
Partial thromboplastin time (sec)	27.4s	Platelet aggregation	
Fibrinogen (mg/dl)	271	Ristocetin	negative [#]
Fibrin degradation product (μ g/ml)	1.68	Epinephulin	positive [#]
Antithrombin III (%)	133	Collagen	positive [#]

vWF: von Willebrand factor, GP: glycoprotein

[#]: These findings are typical in Bernard-Soulier Syndrome.

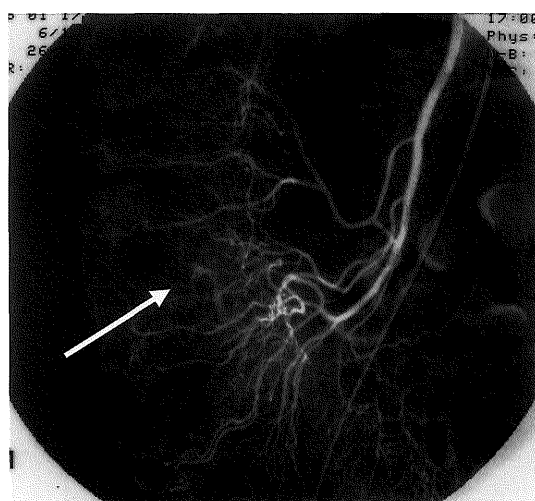


Fig. 1. A selective angiography of the ileocecal artery revealed extravasation in the cecum, which was diagnosed as angiodysplasia.

of cecal bleeding was observed (Fig. 1). Embolization was performed and was successful in controlling the bleeding immediately. Although no melena occurred for three weeks, the liver metastases progressed and developed in to hepatic failure. Three weeks after embolization, she had recurrent melena. As her disease state developed in to hepatic failure with hepatic encephalopathy from severe liver metastasis, her family asked for palliative therapy. It was decided that there were no indications for the endoscopic hemostatic method, interventional procedure or surgical treatment. She died 4 weeks after embolization, and the family refused an autopsy.

DISCUSSION

Bernard-Soulier syndrome is an autosomal recessive bleeding disorder characterized by giant platelets, thrombocytopenia, and prolonged bleeding, and is a very rare disorder found in less than 1 in a million people^{3,6}. The bleeding tendency associated with BSS is usually evident from early childhood, but more severe bleeding episodes are

associated with surgical procedures, dental extractions, menses or accidents^{6,8}. It is known that the platelet membrane glycoprotein (GP) Ib/IX/V complexes, the platelet receptor for von Willebrand factor (vWf), are defective in this syndrome⁶. Absent GP Ib/IX/V complexes on the platelet membrane prevent platelets from sticking to the injured vessel walls, and consequently patients have bleeding problems. The vWf adheres to the subendothelial matrix in injured vessels, then leads to the adhesion of platelets via the binding to GP Ib/IX/V complex and/or GP IIb/IIIa complex existing on the surface membrane^{5,9}. Therefore, vWf, GP Ib/IX/V complex and GP IIb/IIIa complex are important for maintaining the vascular formation or hemostasis of injured vessels⁷. In contrast, abnormalities of vWf, GP Ib/IX/V complex and GP IIb/IIIa complex in von Willebrand disease, BSS and thrombasthenia, respectively, result in not only a bleeding problem but also the development of angiodysplasia in the digestive organs. In our case, she had had a bleeding problem from childhood and first received a blood transfusion as an elementary school student. There are only four case reports in the literature describing BSS with GI angiodysplasia and some treatment options for GI angiodysplasia with BSS are reported^{2,7,12} (Table 2). Although estrogen-progesterone therapy has been attempted in GI angiodysplasia or angiodysplasia^{2,11}, its effectiveness is not clear. Endoscopy is often performed for diagnosis and further manipulation for gastrointestinal angiodysplasia with bleeding and may decrease re-bleeding¹. In addition, angiographic embolization is preferred in severely ill patients who are not good candidates for surgery because of the high rate of complications⁴. Okamura et al reported successful endoscopic treatment in one case with a solitary lesion by clipping and another with asynchronous multiple lesions by clipping and cauterization without re-bleeding⁷. On the other hand, in this case, she had re-bleeding the day after endoscopic therapy and three weeks after angiographic embolization. The pancytopenia by

Table 2. Reported cases of gastrointestinal angiodysplasia with Bernard-Soulier syndrome

Reference	Year	Age	Gender	Location	Number	Therapy				Other disease	Defect of GP	Outcome	Note
						endo- scopic	embo- lization	surgery	hormonal				
Bellucci S. ²⁾	1995	50	M	duodenum colon	multiple	-	-	-	+ (-)	hepatitis B hepatitis C	GPIb	22M/alive	
Okamura ⁷⁾	1996	45	M	stomach jejunum colon	multiple	+ (-)	-	+ (-)	-		GPIb α	45M/alive	consan- guineous
	1996	54	M	stomach	solitary	+ (-)	-	-	-		GPIX	unknown	
Yuksel O. ¹²⁾	2004	39	F	stomach jejunum colon	multiple	+ (-)	+ (+)	+ (-)	+ (+)		un- known	81M/alive	
our case	2004	48	F	cecum	solitary	+ (+)	+ (+)	-	-	hepatitis C metastatic breast cancer	GPIb α	1M/dead	

GP: glycoprotein, Hormonal: oestrogen/progestative therapy
(+): with rebleeding, (-): without rebleeding

chemotherapy and hepatic failure may have been related to re-bleeding. But these hemostatic therapies, which need secondary thrombogenesis, in themselves may not show a persistent hemostasis effect in BSS. Therefore, surgical treatment was considered in our case. However, she and her family did not expect to have a palliative operation because of her poor prognosis from recurrent breast cancer and hepatic failure.

In conclusion, GI angiodysplasia with BSS may be problematic due to re-bleeding, as shown in this case. Endoscopy and angiographic embolization are useful for hemostasis, but re-bleeding may occur. Surgical treatment should be considered if the bleeding point is localized and the general condition can tolerate a surgical procedure.

ACKNOWLEDGMENTS

We thank Mr. Y. Satoh and Dr. K. Okita for clinical advice about endoscopic therapy.

(Received July 21, 2005)

(Accepted September 22, 2005)

REFERENCES

1. Askin, M.P. and Lewis, B.S. 1996. Push enteroscopic cauterization: long-term follow-up of 83 patients with bleeding small intestinal angiodysplasia. *Gastrointest. Endosc.* **43**: 580–583.
2. Bellucci, S., Zini, J.M., Bitoun, P., Dupuy, E., Drouet, L., Tobelem, G. and Caen, J.P. 1995. Diffuse severe digestive angiodysplasia in Bernard-Soulier syndrome. Improvement of bleeding by oestrogen/progestative therapy. *Thromb. Haemost.* **74**: 1610–1612.
3. Bennett, J.S. and Shattil, S.J. 1990. Congenital qualitative platelet disorders, p. 1407–1419. In W.J. Williams, E. Beutler and A.J. Erslev (eds.), *Hematology*, 4th ed. McGraw-Hill, New York.
4. Darcy, M. 2003. Treatment of lower gastrointestinal bleeding. Vasopressin infusion versus embolization. *J. Vasc. Interv. Radiol.* **14**: 535–543.
5. Girma, J.P., Meyer, D., Verweij, C.L., Pannekoek, H. and Sixma, J.J. 1987. Structure-function relationship of human von Willebrand factor. *Blood* **70**: 605–611.
6. Lopez, J.A., Andrews, R.K., Afshar-Kharghan, V. and Berndt, M.C. 1998. Bernard-Soulier syndrome. *Blood* **91**: 4397–4418.
7. Okamura, T., Kanaji, T., Osaki, K., Kuroiwa, M., Yamashita, S. and Niho, Y. 1996. Gastrointestinal angiodysplasia in congenital platelet dysfunction. *Int. J. Hematol.* **65**: 79–84.
8. Peters, M. and Heijboer, H. 1998. Treatment of a patient with Bernard-Soulier syndrome and recurrent nosebleeds with recombinant factor VIIa. *Thromb. Haemost.* **80**: 352.
9. Ruggeri, Z.M. and Ware, J. 1992. The structure and function of von Willebrand factor. *Thromb. Haemost.* **67**: 594–599.
10. Sobin, L.H. and Wittekind, C. (eds.) 2002. TNM classification of malignant tumors. 6th ed., p. 21–23, John Wiley & Sons, New York.
11. van Cutsem, E., Rutgeerts, P. and Vantrappen, G. 1990. Treatment of bleeding gastrointestinal vascular malformation with oestrogen-progesterone. *Lancet* **335**: 953–955.
12. Yuksel, O., Koklu, S., Ucar, E., Sasmaz, N. and Sahin, B. 2004. Severe recurrent gastrointestinal bleeding due to angiodysplasia in a Bernard-Soulier patient. An onerous medical concomitance. *Dig. Dis. Sci.* **49**: 885–887.