

Vascular Access Intervention by Nephrologist in Hiroshima

Shigehiro Doi, M.D. ¹, Ph. D. and Takao Masaki, M.D, Ph. D. ²

¹Department of Blood Purification, Hiroshima University Hospital,
Hiroshima, Japan

²Department of Nephrology, Hiroshima University Hospital,
Hiroshima, Japan

KEY WORDS: Vascular Access Intervention (VAI);
Guidewire Crossability;
Balloon Dilatation;
Management of Complication

RUNNING HEAD: Vascular Access Intervention by Nephrologist

WORD COUNTS: abstract 64 words; text 1727 words

***CORRESPONDENCE TO:**

Shigehiro Doi, M.D., Ph.D. Assistant Professor
Department of Blood Purification, Hiroshima University
Hospital

1-2-3 Kasumi, Minami-Ku, Hiroshima 734-8551, Japan

E-mail: sdoi@hiroshima-u.ac.jp

TEL: +81-82-257-5960

FAX: +81-82-256-5560

Abstract

Background: Vascular access intervention (VAI) is a procedure essential to the maintenance of patency in vascular access and has become indispensable to nephrologists. This procedure has changed nephrology to a more exciting field.

Concept: This report describes the VAI technique which is based on 15 years of treatment experience of the author of this report and which the author has taught to young nephrologists in Hiroshima.

KEY WORDS: Vascular Access Intervention (VAI); Guidewire Crossability; Balloon Dilatation; Management of Complication

Insertion of sheath

Stenosis of arteriovenous fistula (AVF) occurs most often at an anastomotic site and its surroundings. Thus, a sheath is frequently inserted from the main shunt toward the anastomotic site. For an arteriovenous graft (AVG), a sheath is inserted from the lowest part of a loop graft toward the venous side. The sheath is one Fr size larger than the size suitable for the intended balloon catheter. This size sheath is used because, for AVG, stenosis often occurs some distance from the sheath insertion site, such as at the brachial vein. Thus, a long shaft balloon are frequently used. When contrast-enhanced imaging is performed with the balloon catheter pulled back, a guidewire (GW) need to be also pulled back some distance. In some rare cases that a vascular rupture occur, the GW can become positioned past the lesion site. Contrast-enhanced imaging is essential with the balloon catheter inserted to prevent this type of a situation. This problem can be addressed by the use of a sheath that is one Fr size larger than the size suitable for the balloon catheter. There is also an advantage that contrast-enhanced imaging can be performed without avascularization of the arterial side at the time of dilatation of stenosis.

GW crossability patterns

The procedure of passing a GW through a stenotic lesion can be considered the most important step of VAI. In other words, the success of VAI is determined by GW manipulation. Thus, it is important to understand how a GW passes through a stenotic lesion to improve one's VAI technique. A GW cannot be passed through a stenosis by mere pushing (Fig. 1A). A GW passes through the lesion as its tip is rotated (Fig. 1B).

It is difficult to pass a GW in some patients with AVF, and this difficulty often occurs near the anastomotic site. These patients includes those with well-developed branching, calcification, aneurysm, anastomosis at an acute angle, and blood flow mainly from the distal side of the artery. The key is to have several ways of passing a GW to treat lesions in such patients. Figure 2 shows the patterns for GW passage through an anastomotic stenosis to the proximal side of the artery. Pattern A involves a slow rotation of the GW tip to enable its passage through the stenosis to the proximal side of the artery. It is the most standard method. In Pattern B, a loop of GW is made near the anastomotic site. The loop is released or partially released, and the GW tip is positioned facing the direction of the target vessel for GW passage. Then the GW is used to find the entrance to the proximal side of the artery. In this method, when the loop is released, the GW can advance as though it is caught in the vessel into which it needs to be inserted. The GW needs to be slowly advanced from that site to move toward the proximal side of the artery. As in Pattern B, a loop of GW is made at the anastomotic site in Pattern C. The GW is allowed to make one rotation around itself and then is passed through to the proximal side of the artery. The GW is passed completely through the anastomotic site, and its tip is inserted a sufficient distance into the proximal side of the artery. Subsequently, the loop is released when the GW is slightly strongly pulled back toward the operator. Then a balloon catheter can follow the GW. This method can be effective for the discovery of not only the anastomotic site but also the exit of the aneurysm. In Pattern D, a GW is passed temporarily to the distal side of the artery. It is then pushed strongly at arterial branching or at a site where the wall catches the GW. The GW is bent and passed to the proximal side. If the GW tip remains caught in the distal side of the

artery, the GW is temporarily withdrawn into the balloon catheter and is passed to the proximal side of the artery. In Pattern E, the GW is in a state of reversal of its course, or its tip is reversed after the GW is inserted into the distal side of the artery. While the GW is pulled, it is slightly rotated and is passed through to the proximal side of the artery. This method requires more skills than other methods because the GW is passed into the proximal side of the artery while the GW is being pulled.

If the GW cannot be passed to the proximal side of the artery using the above methods, the GW tip is reshaped and the above methods are attempted again. Or a support catheter for contrast-enhanced imaging is used which enables GW manipulation under ultrasound guidance. If the GW is still unable to pass, the method is changed to a transarterial approach. In any of these methods, it is important to assess the state of the vessel through tactile sensing from the tip of the GW. A key to successful GW manipulation is to advance the GW by paying attention to the sudden loss of resistance during manipulation and to the instance of its forward movement. In addition, the GW has to pass beyond the anastomotic site and has to be inserted a sufficient length into the proximal side of the artery. One reason for this GW insertion of a sufficient length involves an important attitude of humility in this procedure: the attitude that the GW is able to pass through the lesion not because of the operator's skills but because of chance. This type of humility is required in practitioners performing vascular access intervention therapy – the thinking that “if the GW becomes withdrawn out of the lesion, then I will be unable to pass it through the lesion again.” A technical reason is that if vascular rupture is confirmed by postoperative contrast-enhanced imaging, the sufficient GW length enables a prompt delivery of a balloon catheter. If a vascular rupture occurs, the

GW will advance extravascularly from the rupture site even in VA where the GW can be advanced without the use of conventional fluoroscopy. The target vessel for GW insertion collapses, making the passage of GW difficult. Another reason is that if the GW is advanced sufficiently beyond the anastomotic site, the more resilient portion of GW will be located at that site. Therefore, the vessel becomes straightened, facilitating the passage of balloon catheter.

Considerations in balloon dilatation

In balloon dilatation of stenosis, discussion has not been made about the issue of which part of the balloon to use for the dilatation of stenosis. At the 17th Annual Meeting of Vascular Access Interventional Therapy, Haruguchi et al. reported on a study using ultrasound. They found that if dilatation of stenosis is performed in the center of the balloon, the surrounding tissue would become caught by the balloon. Thus, it would be difficult to achieve complete dilatation. The solution is to position the balloon so that its tip is at the stenotic site. Then balloon dilatation will occur as the surrounding tissue is pushed out instead of being caught. Haruguchi et al. reported that this method is effective in dilatation of hard stenosis.

It has been reported that blades of peripheral cutting balloons (PCB) detached despite dilatation of stenosis performed according to the package insert. The cause of detachment of PC was unclear, but the authors speculated that one cause was repeated dilatation of stenosis which still had constriction. When dilatation of stenosis is performed using PCB, it is necessary to avoid dilatation using high pressure over 10 atm and to avoid multiple dilatation attempts, even if stenosis remains. The report also

revealed that the normal pulse mode was not able to detect that the blades were about to detach, that such blades detached when they became caught in sheaths when removing catheters, and that the detached blades left in the body permanently remained there. Similarly, the scoring element of scoring balloons cannot be visually confirmed using the normal pulse mode but can be confirmed using DSA or one-shot imaging. In contrast-enhanced imaging after vasodilatation, it is necessary to confirm the absence of blade detachment while also noting the balloon portion of scoring balloons and PCBs.

Management of complications

Vascular rupture is the most serious complication and requires urgent treatment. Bittl analyzed 1242 patients who had undergone vascular access intervention therapy. Eleven patients (0.9%) had vascular rupture, of whom two required transfusion and eight required stenting (six required covered stents). Bittl reported that the use of a balloon catheter more than 2 mm larger than the diameter of the hemodialysis access and the use of PCB increased the risk of rupture (1). The experience of the author of the present report indicates that effective vascular rupture management is to apply pressure from the body surface with balloon dilatation at low pressure. This method achieved hemostasis in most patients. In balloon dilatation, it is necessary to insert the GW to a sufficient length, to perform imaging after completion of dilatation, and to confirm the absence of rupture before the GW is removed. In clinical practice, the author of the present report gradually increases the pressure 1 atm in approximately 5 seconds, but there is an opinion that inflation can be performed more quickly without a problem. The present author has also encountered patients who developed pulmonary edema soon after dilatation of

anastomotic stenosis on the venous side of the graft and who required an extracorporeal ultrafiltration method. There were also patients who had increased peripheral coldness. Consideration always needs to be given regarding heart failure, pulmonary edema, and peripheral ischemia which can be induced by improved VA blood flow. In addition, vasospasm can be induced by the GW, catheter, or stimulation during vasodilation. Nitroglycerin administration is useful for arterial spasm or spasm in which the GW in the vein has not been passed through a lesion. Direct dilatation using a balloon is useful for spasm in which the GW has passed through the lesion in the vein. Other complications include hematoma, pseudoaneurysm, allergy to contrast media, and allergy to local anesthesia.

Acknowledgement

None

Conflict of interest statement

Authors have declared that no conflict of interest exists.

Reference

1. Bittl JA. Venous rupture during percutaneous treatment of hemodialysis fistulas and grafts. *Catheter Cardiovasc Interv* 2009; 74: 1097-1101

Figure Legends

Figure 1. Principles of GW passing through a stenosis

- A. The GW cannot be passed through a stenosis by merely pushing.
- B. The GW passes through a lesion by rotation.

Figure 2. Patterns of GW passage through anastomotic stenosis

- A. The GW is passed from the tip through the anastomotic site.
- B. A loop is made at the anastomotic site, and the loop is released to find the entrance to the proximal side of the artery.
- C. A loop is made at the anastomotic site, and the GW is passed through the anastomotic site.
- D. The GW is passed to the distal side of the artery, the tip is allowed to get caught, and the GW is bent and inserted into the proximal side.
- E. The course of the GW is reversed, the reversed area is inserted into the distal side of the artery, and the tip is inserted into the proximal side.

Figure 1A.

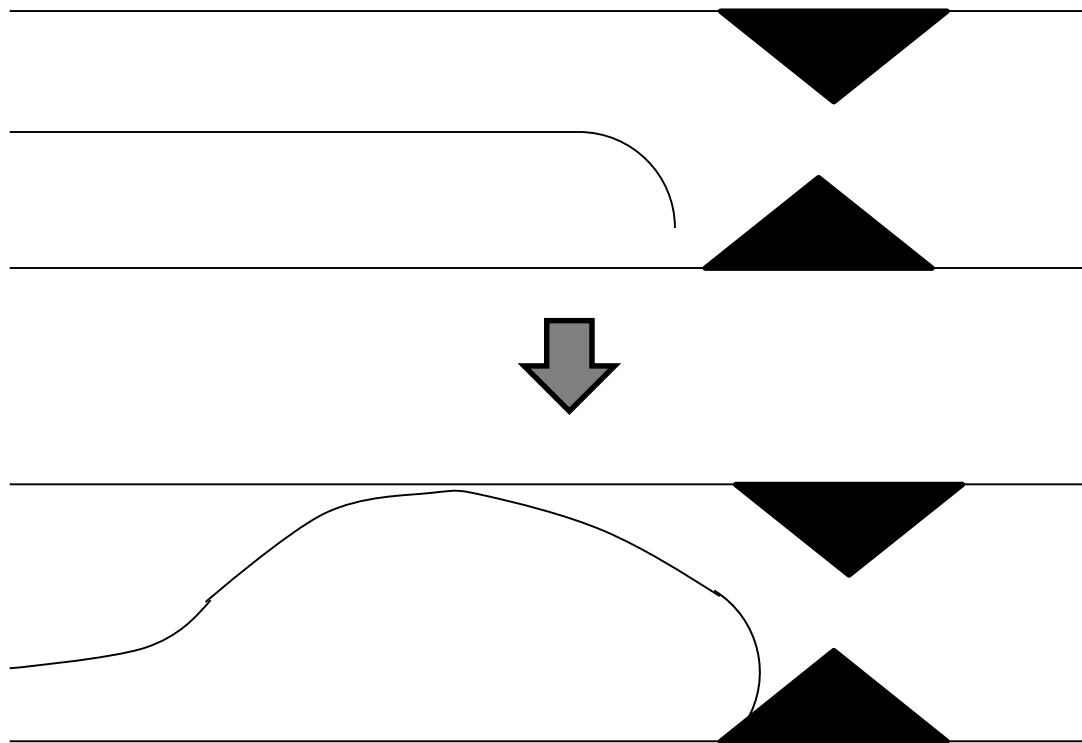


Figure 1B

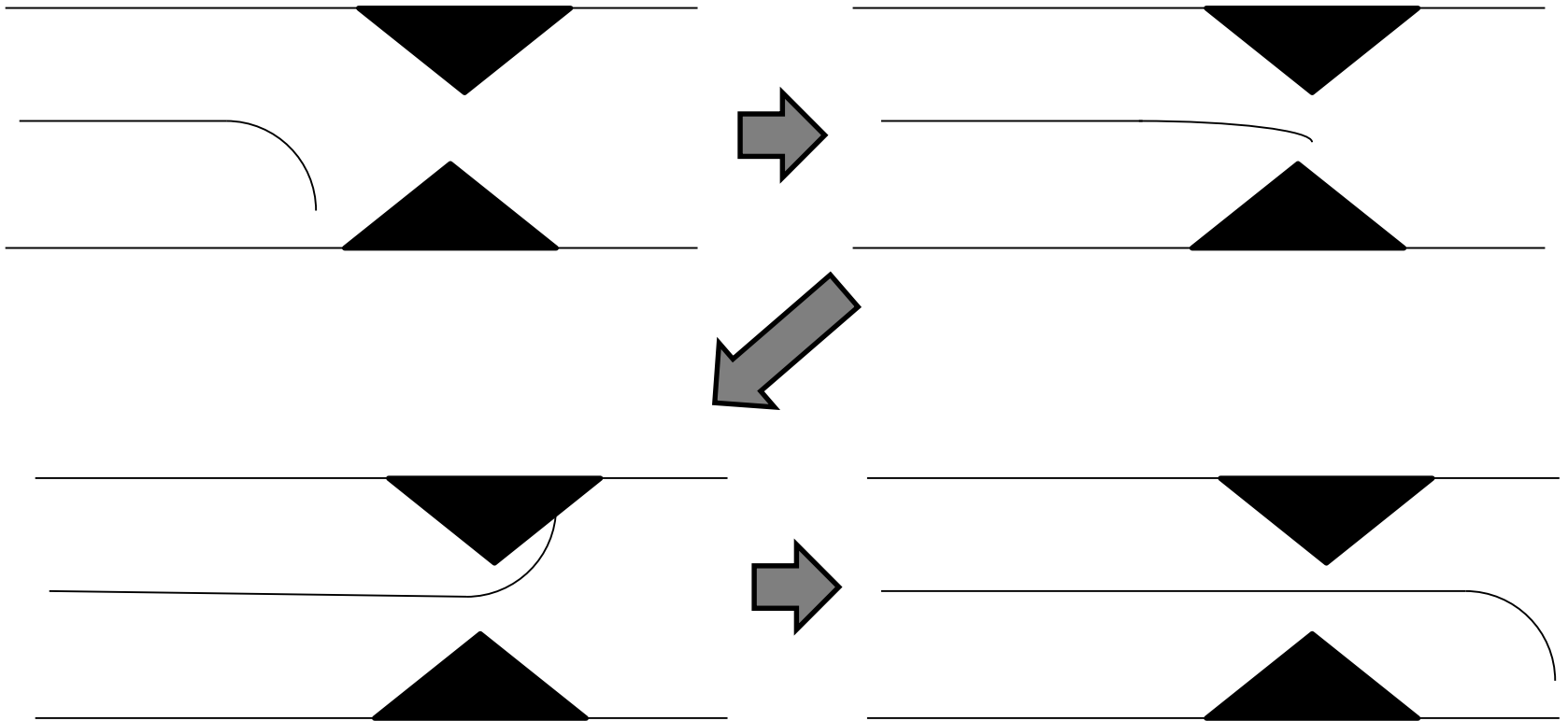


Figure 2A.

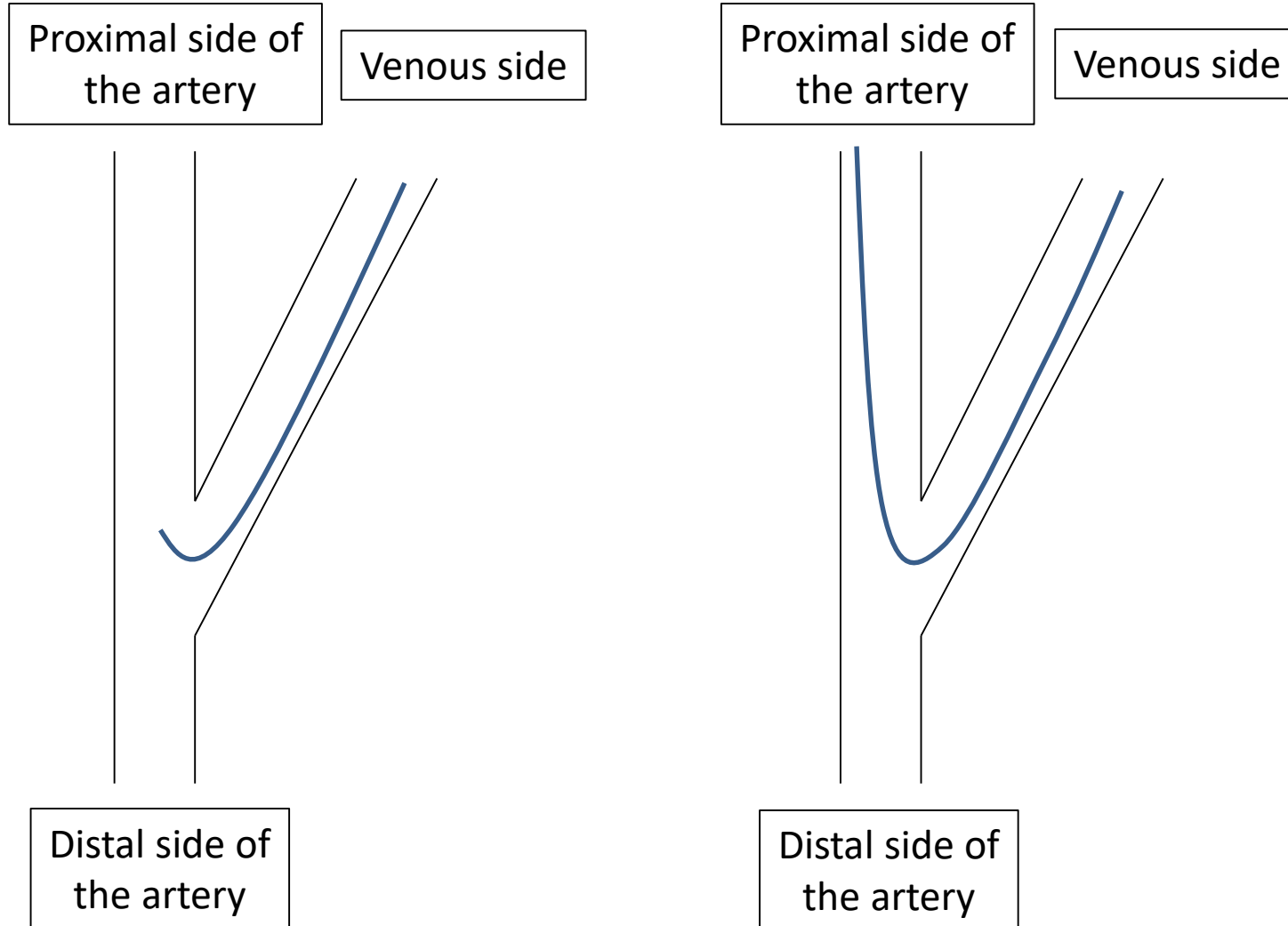


Figure 2B.

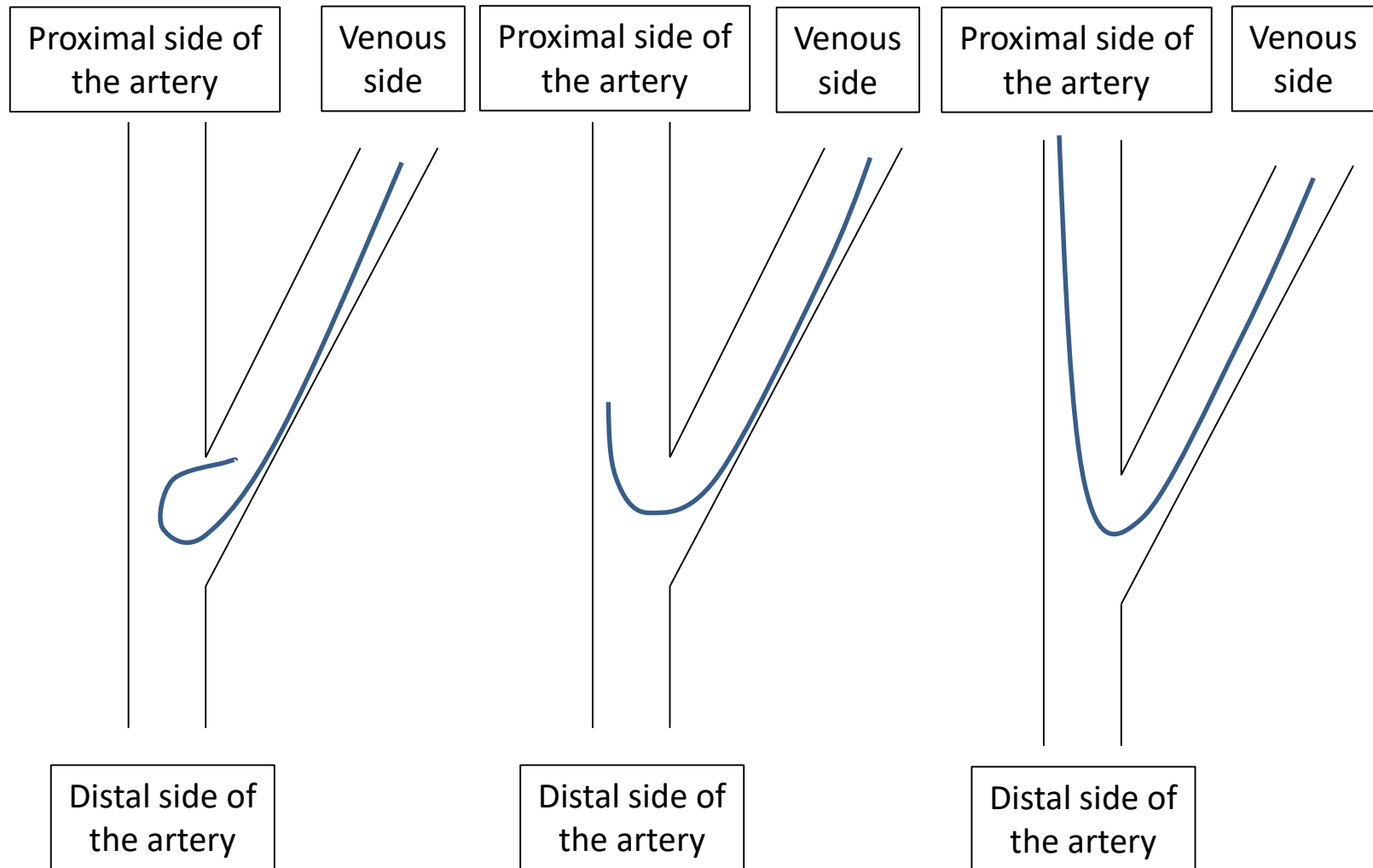


Figure 2C.

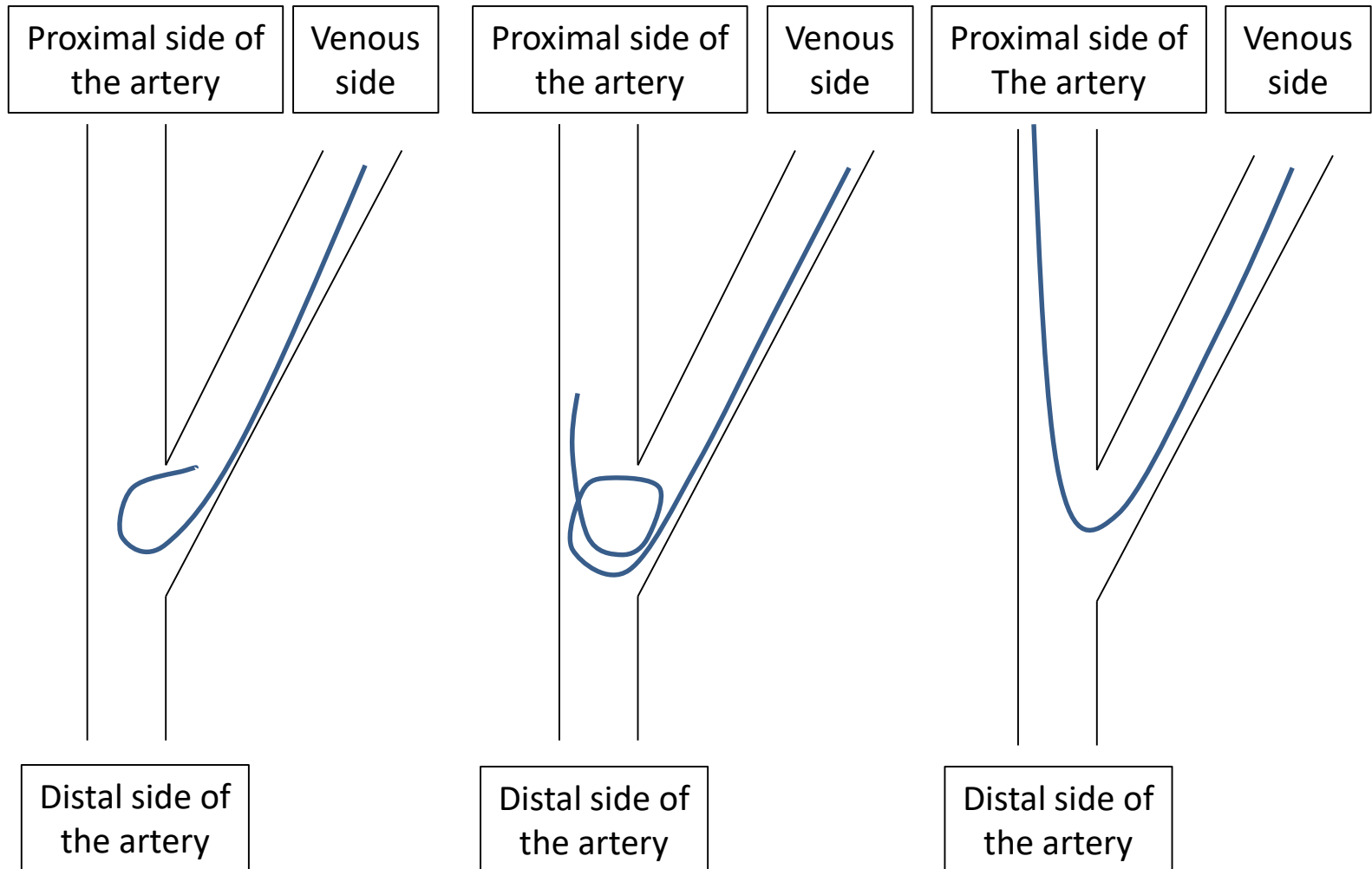


Figure 2D.

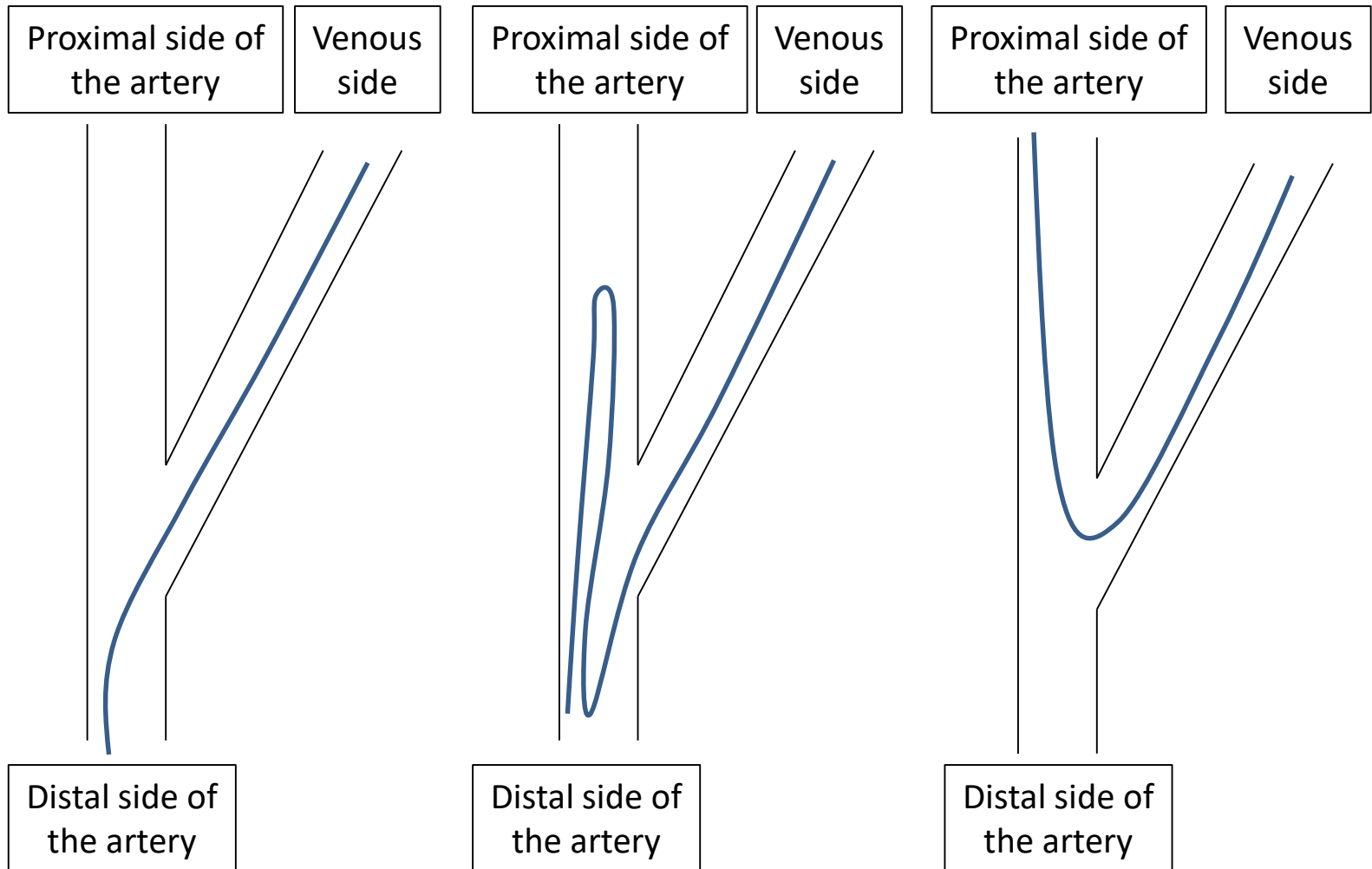


Figure 2E.

