

**Adrenal Venous Sampling by Using Gadopentetate Dimeglumine in Patients
with Contraindications for Iodinated Contrast Agents**

Naoya Mitsuba, MD, Satoshi Kurisu, MD, PhD, Yasuko Kato, MD,
Ken Ishibashi, MD, Yuichi Fujii, MD, PhD, Yoshihiro Dohi, MD, PhD,
Kenji Nishioka, MD, PhD, Yasuki Kihara, MD, PhD

Department of Cardiovascular Medicine, Hiroshima University Graduate
School of Biomedical Sciences, Hiroshima, Japan

Short title: Adrenal venous sampling by using gadolinium

No grant

Correspondence to:

Satoshi Kurisu, MD

1-2-3, Kasumi-cho, Minami-ku,

Hiroshima, 734-8551, Japan

Phone:+81-82-257-5540

Fax:+81-82-257-1569

E-mail: skurisu@nifty.com

Figure : 2

Word counts : 987

Primary aldosteronism, which is characterized by hypertension, hypokalemia, decreased plasma renin activity (PRA) and increased aldosterone secretion, can be caused by both unilateral and bilateral adrenal lesions [1-3]. It is important to distinguish unilateral lesion from bilateral lesion because unilateral lesion is a curable form of secondary hypertension. The most reliable examination remains adrenal venous sampling guided by adrenal venography [4]. Iodinated contrast agents are routinely used in angiography. Anaphylactoid reaction to iodinated contrast agents is a rare, but life-threatening complication of angiography [5,6]. The use of gadolinium contrast agents of visceral, peripheral, carotid or coronary arteries has been recently reported in patients with contraindications for iodinated contrast agents or renal insufficiency [7-10]. In this report, we describe 2 cases of primary aldosteronism as well as contraindications for iodinated contrast agents, in which gadopentetate dimeglumine, gadolinium chelated by DTPA, was used as an alternative contrast agent for adrenal venography.

A 63-year-old woman presenting with hypertension was admitted to our hospital. She had a history of anaphylactoid reaction to iodinated contrast

agents. The laboratory data were as follows: creatinine, 0.57 mg/dl; PRA, 0.8 ng/ml/hr; plasma aldosterone concentration (PAC), 31.9 ng/dl; PAC to PRA ratio, 39.9. Confirmatory tests including captopril challenge test and furosemide plus upright test were positive. She was diagnosed as having primary aldosteronism. Plain computed tomography showed no adrenal tumor. She requested adrenal venous sampling by using gadolinium after explaining its risks and benefits. After written informed consent was obtained, adrenal venous sampling was performed through the right femoral vein. A 5-French catheter was positioned with its tip in the right or left adrenal vein. Gadopentetate dimeglumine was diluted 1:1 with sodium chloride before application. Gadopentetate dimeglumine was used for test injection to confirm catheter position, and anterior and lateral views of adrenal venography were obtained with acceptable quality by using this agent (Figure 1). Adrenal venous sampling was subsequently performed after adrenocorticotrophic hormone (ACTH) stimulation. The total volume of gadopentetate dimeglumine was 12 ml. No adverse effects occurred during and after the procedure. She was diagnosed as having bilateral adrenal hypersecretion, and treated with eplerenone.

A 64-year-old woman presenting with hypertension was admitted to our hospital. The laboratory data were as follows: creatinine 0.52 mg/dl; PRA, 0.4 ng/ml/hr; PAC, 11.7 ng/dl; PAC to PRA ratio 29.3. Confirmatory tests including captopril challenge test and furosemide plus upright test were positive. She was diagnosed as having primary aldosteronism. The abdominal computed tomography showed a mass of 15 mm in the left adrenal which was poorly enhanced after contrast enhancement. After the contrast-enhanced computed tomography examination, she complained of itching and dyspnea, which required a treatment with oxygen and infusion. The timing of these symptoms suggested an anaphylactoid reaction to the iodinated contrast agents. She requested adrenal venous sampling by using gadolinium after explaining its risks and benefits. After written informed consent was obtained, adrenal venous sampling was performed through the right femoral vein. A 5-French catheter was positioned with its tip in the right or left adrenal vein. Gadopentetate dimeglumine was diluted 1:1 with sodium chloride before application. Gadopentetate dimeglumine was used for test injection to confirm catheter position, and anterior and lateral views of adrenal venography were obtained with acceptable quality by using this

agent (Figure 2). Adrenal venous sampling was subsequently performed after ACTH stimulation. The total volume of gadopentetate dimeglumine was 9 ml. No adverse effects occurred during and after the procedure. She was diagnosed as having bilateral adrenal hypersecretion, and treated with eplerenone.

Enhanced computed tomography is useful in planning adrenal venous sampling by demonstrating the anatomy and positions of the adrenal veins. However, patients with contraindications for iodinated contrast agents receive limited benefit from computed tomography because of no enhanced imaging. It is important to recognize the anatomy of adrenal veins by venography for obtaining good samples, and adrenal venous sampling should be performed by experienced operators [3,4].

Major adverse effects of iodinated contrast agents are rare with the widespread use of non-ionic contrast agents [5,6]. However, anaphylactoid reaction to the iodinated contrast agents is still a major complication of angiography. Alternative methods that permit invasive imaging of adrenal veins are required in patients with contraindications to iodinated contrast

agents. One potential method for these conditions is to use corticosteroid for preventing anaphylactoid reaction to iodinated contrast agents before angiography [11]. However, there has been no clinical data assessing how much pretreatment with corticosteroid affect the results of adrenal venous sampling. We did not choice this method to obtain as reliable results as possible. The other potential method is to use gadolinium as an alternative contrast agent. Nelson et al reported that adverse reactions occurred in 2.4% of patients receiving this agent for magnetic resonance imaging. They also reported that patients with previous reactions to iodinated contrast agent had an adverse reaction rate of 6.3% [12]. Kalsch et al used gadolinium for coronary angiography in 19 patients with contraindications to iodinated contrast agents, and reported that 21% of the patients suffered complications due to gadolinium application such as malignant arrhythmias or hemodynamic decompensation [10]. These complications might result from non-physiological osmolality rather than gadolinium itself. In patients with renal insufficiency, nephrogenic systemic fibrosis has been reported to be a rare, but life-threatening complication associated with the use of gadolinium [13].

There have been few reports concerning the use of gadolinium for venography. However, we used gadopentetate dimeglumine for adrenal venography after assessing its risk and benefit in our cases of contraindications for iodinated contrast agents and normal renal function. Consequently, adrenal venograms were obtained with reduced, but acceptable quality. No adverse reaction occurred. The use of gadolinium is associated with an increased expense. However, only a little amount of gadolinium is required when adrenal venous sampling is performed by experienced operators.

In conclusion, gadopentetate dimeglumine may be a suitable alternative contrast agent for adrenal venography in patients with contraindications for iodinated contrast agents. Our findings require further confirmation by larger patient numbers.

REFERENCES

- [1] Conn JW. Primary aldosteronism. *J Lab Clin Med* 1955;45:3-17.
- [2] Gordon RD. Mineralocorticoid hypertension. *Lancet* 1995;344:240-243.
- [3] Stowasser M, Gordon RD, Rutherford JC, Nikwan NZ, Daunt N, Slater GJ. Diagnosis and management of primary aldosteronism. *J Renin Angiotensin Aldosterone Syst* 2001;2:156-169.
- [4] Veglio F, Morello F, Rabbia F, Leotta G, Mulatero P. Recent advances in diagnosis and treatment of primary aldosteronism. *Minerva Med* 2003;94:259-365.
- [5] Lieberman P. Anaphylactoid reactions to radio-contrast material. *Clin Rev Allergy* 1991;9:319-338.
- [6] Cochran ST. Anaphylactoid reactions to radiocontrast media. *Curr Allergy Asthma Rep* 2005;5:28-31.
- [7] Kinno Y, Odagiri K, Andoh K, et al. Gadopentetate dimeglumine as an alternative contrast material for use in angiography. *AJR Am J Roentgenol* 1993;160:1293-1294.
- [8] Zeller T, Muller C, Frank U, et al. Gadodiamide as an alternative contrast agent during angioplasty in patients with contraindications to iodinated

media. *J Endovasc Ther* 2002;9:625-632.

[9] Kaufman JA, Hu S, Geller SC, Waltman AC. Selective angiography of the common carotid artery with gadopentetate dimeglumine in a patient with renal insufficiency. *AJR Am J Roentgenol* 1998;172:1613-1614.

[10] Kalsch H, Kalsch T, Eggebrecht H, et al. Gadolinium-based coronary angiography in patients with contraindication for iodinated X-ray contrast medium: a word of caution. *J Interv Cardiol* 2008;21:167-174.

[11] Wittbrodt ET, Spinler SA. Prevention of anaphylactoid reactions in high-risk patients receiving radiographic contrast media. *Ann Pharmacother* 1994;28:2236-241.

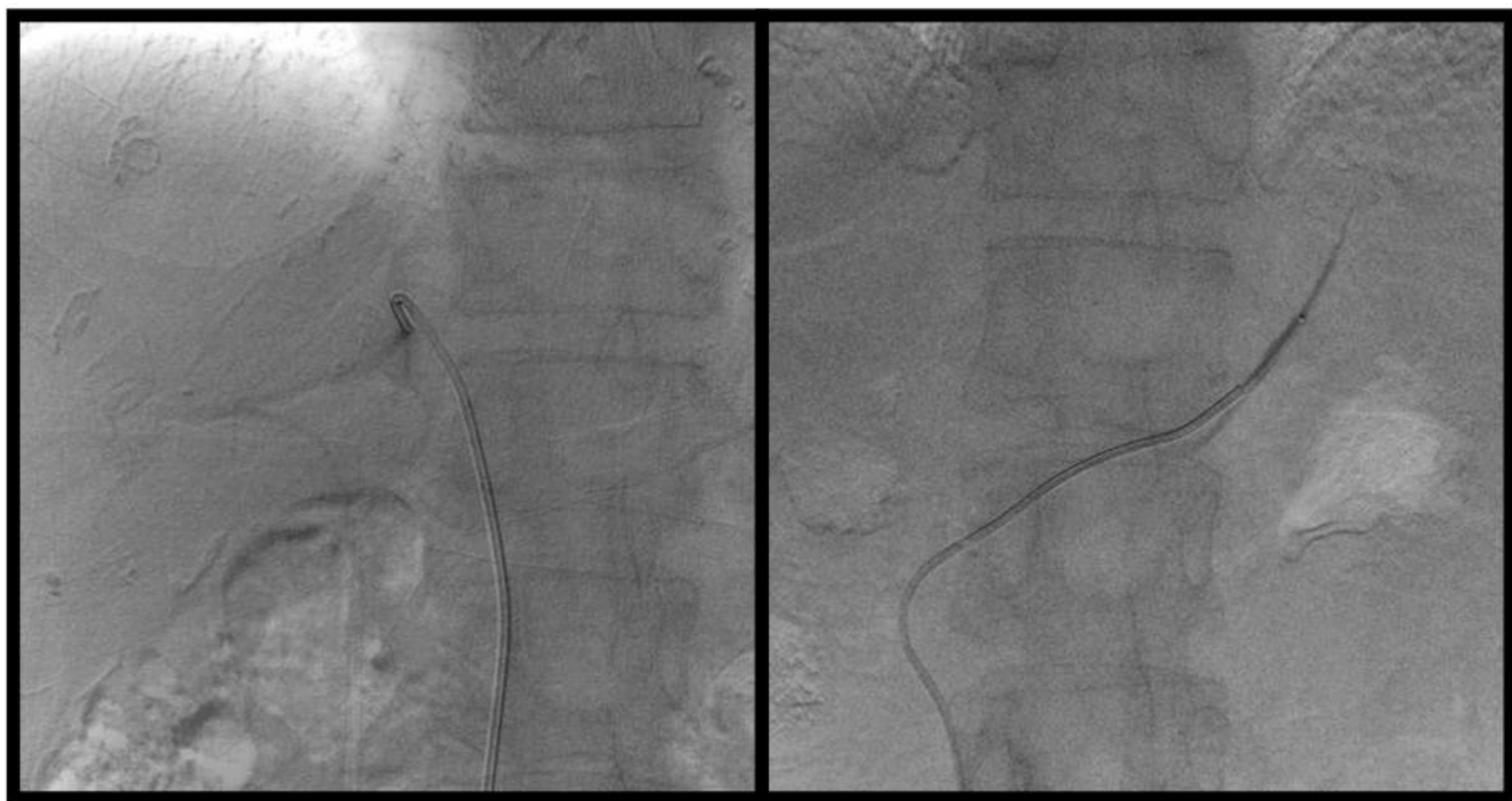
[12] Nelson KL, Gifford LM, Lauber-Huber C, Gross CA, Lasser TA. Clinical safety of gadopentetate dimeglumine. *Radiology* 1995;196:439-443.

[13] Haemel AK, Sadowski EA, Shafer MM, Djamali A. Update on nephrogenic systemic fibrosis: are we making progress? *Int J Dermatol* 2011; 50:659-666.

FIGURE LEGEND

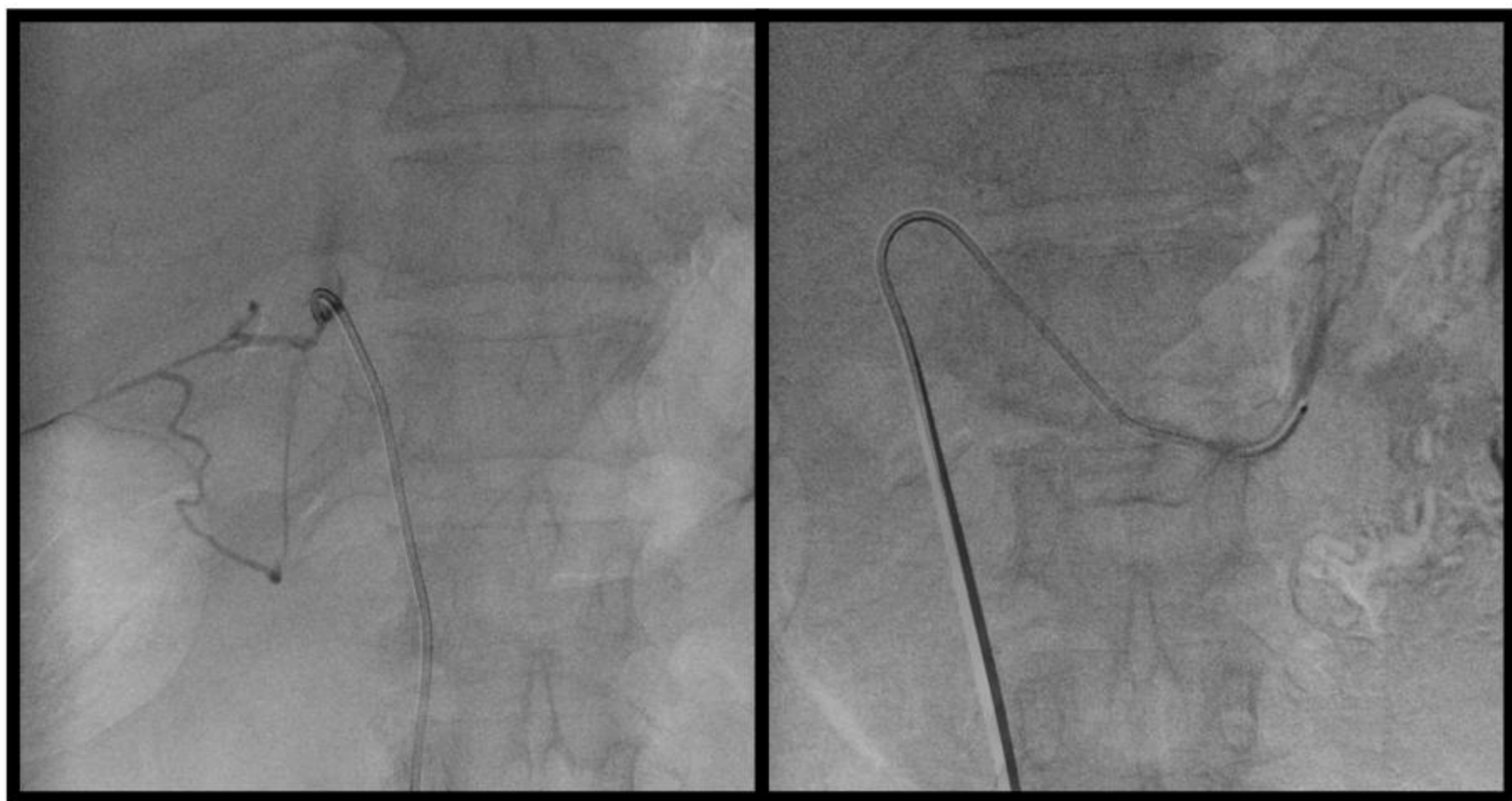
Figure 1 Right and left adrenal venograms in case 1 by using gadopentetate dimeglumine. These were obtained with reduced, but acceptable quality.

Figure 2 Right and left adrenal venograms in case 2 by using gadopentetate dimeglumine. These were obtained with reduced, but acceptable quality.



Right adrenal vein

Left adrenal vein



Right adrenal vein

Left adrenal vein